

The 65th ASH Annual Meeting Abstracts

POSTER ABSTRACTS

621.LYMPHOMAS: TRANSLATIONAL-MOLECULAR AND GENETIC

Performance of a Liquid Biopsy Diagnostic Prediction Model for EBV-Positive Burkitt Lymphoma in Sub-Saharan Africa

Clara C Chamba, MD MMed¹, Kieran Howard², William F Mawalla, MD¹, Heavenlight Christopher, MSc¹, Julius Seruyange³, Emmanuel Josephat, MSc¹, Ismail D Legason, MSc,BSc,MPH⁴, Martin Ogwang⁴, Alisen Ayitewala, MSc³, Alex Mremi, PhD⁵, Caroline Achola, MBChB, MMed(Path)³, Edrick Elias^{6,7}, Anthony Cutts², Helene Dreau, MSc², Adam Burns, PhD², Rehema Shungu⁸, Sila Gerlevik², Daisy Jennings, MSc⁹, Emmanuel Balandya¹⁰, Kate Ridout, PhD², Hadija Mwamtemi, MD MMed¹¹, Priscus Mapendo¹², Eli Mkwizu¹², Claire El Mouden, DPhil², Dimitris Vavoulis², Anna Schuh, MDPH FRCP, FRCPath², AI-Real Consortium^{8,11,12,7,4,3,2}

¹Department of Haematology and Blood Transfusion, Muhimbili University of Health and Allied Sciences, Dar-es-Salaam, Tanzania, United Republic of

²Department of Oncology, University of Oxford, Oxford, United Kingdom

³Central Public Health Laboratories, Kampala, Uganda

⁴St. Mary's Hospital Lacor, Gulu, Uganda

⁵Kilimanjaro Christian Medical Centre, Moshi, Tanzania, United Republic of

⁶Catholic University of Health and Allied Sciences, Mwanza, Tanzania, United Republic of

⁷Bugando Medical Centre, Mwanza, Tanzania, United Republic of

⁸Department of Hematology and Blood Transfusion, Muhimbili University of Health and Allied Sciences, Dar-es-Salaam, Tanzania, United Republic of

⁹Nuffield Department of Medicine, University of Oxford, Oxford, United Kingdom

¹⁰Department of Physiology, Muhimbili University of Health and Allied Sciences, Dar-es-Salaam, Tanzania, United Republic of

¹¹Department of Paediatrics, Muhimbili National Hospital, Dar-es-Salaam, Tanzania, United Republic of

¹²Department of Oncology, Kilimanjaro Christian Medical Centre, Moshi, Tanzania, United Republic of

Burkitt Lymphoma (BL) is classified into EBV-positive BL (EBL) and EBV-negative BL (sporadic BL), the former being more prevalent in SSA (Al-Khreisat et al 2023). Conventional diagnosis of BL depends on the morphological assessment of invasive tissue biopsy followed by immunohistochemistry (IHC) and fluorescent in situ hybridization (FISH) to reveal the pathognomonic t(8;14), or t(8;22) translocations. This is associated with significant diagnostic delay in regions with limited pathology services (Mawalla et al 2023), often necessitating initiation of treatment based on clinical or histopathological findings without immunohistochemistry (Ogwang et al 2011), with ensuing mismanagement contributing to poor survival outcomes observed in SSA compared to High-Income Countries (HIC) (Sung et al 2021).

Here, we sought to explore whether liquid biopsy could be used as an initial diagnostic aid for EBL in settings without easy access to pathology using different EBV DNA parameters and the MYC-Immunoglobulin (MYC-Ig) gene rearrangement.

This prospective study collected whole blood samples prospectively from 221 participants (90 BL and 131 non-BL) enrolled in the Aggressive Infection-Related East Africa Lymphoma (AI-REAL) project (Legason et al 2022) across 5 sites in Tanzania and Uganda. The revised BL diagnostic algorithm (Naresh et al 2021) was used as a gold-standard diagnosis. cfDNA was extracted using the QIAamp Circulating Nucleic Acid Kit (Qiagen, USA), according to the manufacturer's instructions. DNA libraries were prepared with the Thru PLEX Tag-Seq HV kit (Takara Bio Inc. Japan), and hybridization capture was performed using a custom, next-generation sequencing (NGS) panel targeting genes commonly mutated in BL and three EBV genes: *EBER1*, *EBER2*, and *EBNA2*. All sequencing was performed in-country (MiSeq, Illumina, CA, USA) and analyzed in a custom pipeline.

Using custom scripts, EBV DNA copies per cell and EBV DNA fragment size ratio were calculated as the proportion of EBV fragments of length 180 - 200 base pairs (bp) divided by the proportion of autosomal fragments within the same size window. The diversity in the fragment size distribution of the EBV and autosomal DNA was calculated and presented as EBV

entropy and autosomal entropy. Translocations were called using IgCaller (Nadeu et al 2020) and Genomic Rearrangement Identification Software Suite (GRIDSS) (Cameron et al 2017).

Univariate analysis was performed to assess the association between predictor variables (clinical parameters, EBV parameters, and *MYC* translocation) and a diagnosis of EBL. Ten-fold cross-validation was performed on a liquid biopsy model consisting of all the liquid biopsy variables with the clinical variables included in the model as covariates. Performance metrics for the liquid biopsy model as a diagnostic aid were calculated, and variable importance was determined to assess each variable's relative influence on the model.

In our cohort, EBL diagnosis was negatively associated with tumor site (neck) and not significantly associated with tumor site (jaw). A shorter duration of symptoms was associated with a diagnosis of EBL. Presence of *MYC* translocation t(8;14), higher EBV fragment size ratio, proportion, entropy, and copies per cell for *EBER1*, *EBER2*, and *EBNA2* were all associated with a diagnosis of EBL. The combined liquid biopsy diagnostic prediction model had an estimated AUC of 90%, with sensitivity between 85%-90%, specificity between 75% - 80%, and positive and negative predictive values of 85% (Figure 1). *MYC* translocation t(8;14) was the most important diagnostic variable, followed by EBV entropy (Figure 2).

This study demonstrates the feasibility of liquid biopsy as a non-invasive diagnostic aid for EBL in settings without easy access to pathology. To strengthen the application of this technology into clinical practice, further analysis is being conducted for weighting and assigning of scores for each predictor variable. This would assist clinicians in making a precise diagnosis, complementing existing diagnostic modalities for EBL, and reducing the rate of misdiagnosis arising from diagnosis based on clinical suspicion and tissue morphology without immunohistochemistry.

Disclosures No relevant conflicts of interest to declare.

<https://doi.org/10.1182/blood-2023-186131>

Figure 1: Association between predictor variables and EBL (Univariate analysis)

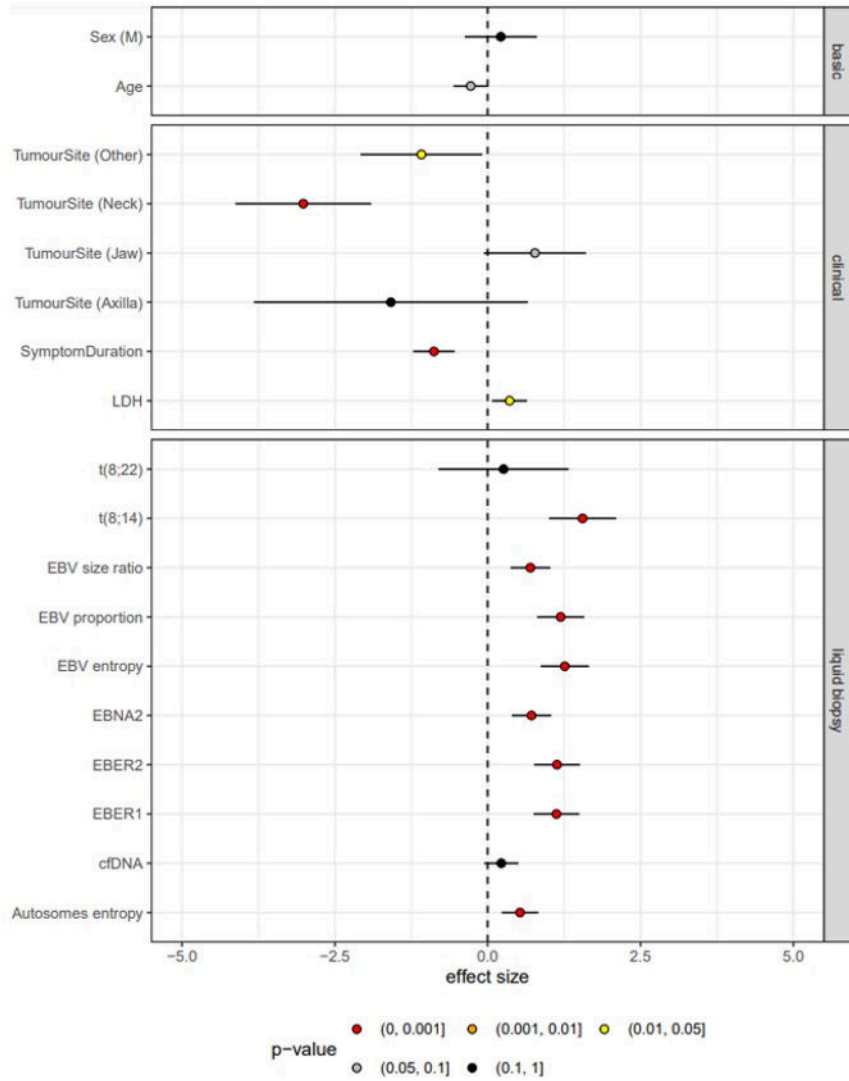


Figure 1

Figure 2: Performance characteristics of the Liquid Biopsy diagnostic prediction model

